

---

## Feature Article

---

### The Use of Electrolysis for the Treatment of Minor Skin Blemishes

In 1875 the very first treatment using electrolysis was recorded in 'The Lancet' for trichiasis (in-growing eyelashes). Since this time, further developments have established its position as a successful and popular treatment for permanent hair removal for both medical and cosmetic reasons. Indeed it still is the only form of permanent hair removal that works for all skin and hair types and colours legally allowed to make that claim.

Advanced electrolysis is historically considered a relatively new development but the book, 'Electricity in Facial Blemishes' by Plym S Hayes M.D. (the late professor of chemistry and toxicology at the Chicago College of Pharmacy), published in 1910, suggested that many of the treatments have been around almost as long as electrolysis hair removal.

His book featured electrolysis treatment of many blemishes including: "*port-wine marks, pigmentary naevi, fibromata, naevus verrucosus and warts, naevus vasculosus simplex, angioma cavernosum, telangiectasis, naevus araneus and even xanthoma palpebra.*"

So historically the effective results of electrolysis were quickly put to other uses and its true versatility was recognised in the development of techniques for the treatment of a number of minor skin conditions and imperfections. Other treatments have been added to Hayne's impressive list and techniques honed and improved for other conditions such as sebaceous cysts and syringoma to mention just a few.

At the forefront of the development and popularity of these techniques is Sterex Electrolysis International Limited where Elaine Stoddart, Director of Education and electrolysis specialist has developed, marketed and popularised this versatility.

There are now over 21 different types of blemishes that can be safely and effectively treated using electrolysis modalities and currently Sterex hold monthly Advanced 2+1 day courses and teach practitioners representing all sections of the medical professional.


### What does Advanced Cosmetic Procedures mean?

It is a new name for 'Advanced Electrolysis' plus all the new additional techniques. This speciality treatment uses either Short Wave Diathermy (High Frequency A/C) or Blend (a mixture of A/C and D/C) to remove unwanted skin blemishes with no mark left on the skin.

Consumers appeared to be under the misapprehension that "Advanced Electrolysis" was simply an advanced form of hair removal and were simply not aware of the diversity of treatments which were available using electrolysis as the medium.

The term, Advanced Cosmetic Procedures (ACP), encompassed far more effectively, the wide variety of treatable skin conditions. The new name reinforced the treatments 'medical identity' by association and with a more appealing and up-beat terminology. A simple spin on the name has made it into one of the fastest growing treatments available today.

**Treatable Conditions (Feb 2012) include:** Telangiectasia, Campbell de Morgans, spider naevi, minor telangiectasia on the legs, poikiloderma, skin tags, milia, all types of warts including common, seborrhoeic, plantar (verruca), hairs from moles and moles themselves, age spots, dermatosis papulosa nigra, small sebaceous cysts, sebaceous hyperplasia, sebaceous naevi, xanthomas, syringoma, molluscum contagiosum and the list gets longer and longer as more research and development is carried out.



## Generating clients

The demarcation line between medical and beauty is becoming very hazy. Due to funding implications practitioners within the NHS are now not performing any treatments considered 'cosmetic' and this opens the market up for the consumer to actively look for an alternative.

Not only are these treatments lucrative, rewarding and effective but in many cases they offer instantaneous results. Instant gratification is a strong motivation for recommendation which means attracting clients is often effortless.

In a clinical environment featuring a 'beauty and aesthetic division' the transition from existing 'facial client' to 'Advanced Cosmetic Procedure patient' is relatively straightforward as skin blemishes are easily noted during a facial treatment or body massage. Once the client becomes informed regarding the wide diversity of skin disorders which can be treated, those very disorders will almost certainly be presented to the practitioner. Repeat business is also guaranteed as the client continues to age and his/her complexion, if subject to these disorders, will show further evidence and require on-going treatment.

## Treatment viability and profitability

Generally the patient pays for the length of time he/she is treated and this varies depending on the clinic and area. £50 - £70 for 15 minutes and £85 - £120 for 30 minutes are average figures when beauty therapists/electrologists perform these treatments but qualified Nurses, Doctors and Cosmetic Surgeons charge far more and the figures increase rapidly depending on the level of qualification of the practitioner. Clients pay for results not treatment and are genuinely delighted with the results. For unsightly skin blemishes to be removed in such a quick, easy and effective way patients are so delighted and they feel it is money well spent.

## Training Costs

Sterex ACP training courses are very intensive 2+1 day courses following which considerable practice is recommended to gain experience and expertise. Follow up refresher days are regularly offered and always recommended bi-annually to ensure the practice continuation of proficient and current skills. 2012 fees are £685.00+VAT which includes all course manuals, models provision, luncheon and preferential ACP listing on the Sterex website once qualified. Refresher days are offered at the minimal cost of £100 +VAT.

## Machinery costs

These treatments are performed using Blend electrolysis epilators and most electrologists or beauty salons have existing equipment which can be utilised.

The top of the range Sterex Blend Epilator is £767.84+VAT but discounts are offered at exhibition times. During the FACE show SXB units will be offered VAT free. If the practitioner is charging a minimum £200+ an hour for these treatments the machine and training is paid for in only a few hours of treatment.

The cost of performing the treatment is negligible requiring only a Sterex needle, (approx 32p), Sterex Steritane to sterilise the skin prior to treatment, aftercare products such as Sterex Witch Hazel and Aloe Vera and minor items such as cotton wool, and couch roll. In fact there are few treatments (if any) which are so lucrative to perform.

## What is the risk of scarring?

When the treatments are performed correctly there is little or no chance of permanently marking the skin. Sterex always recommend, when appropriate to try a 'tester patch' in an area which is not too noticeable in case of adverse reaction. This allows the client to 'experience' the feel of the treatment, to see the benefits and for the practitioner to assess the healing rate.

With many of the procedures the appearance may look worse before it looks better and we advise informing the patient that careful 'timing' of the treatment should be considered. The Short Wave Diathermy method has always been popular and is still commonly used for many of the procedures but the Blend method of Telangiectasia (pioneered by Sterex), is a more gentle treatment causing less skin trauma and resulting in quicker healing. Sterex recommend that a month after treatment a follow up consultation is arranged to:

- Assess the skin
- Ensure the patient is completely happy
- Take an after photograph if appropriate
- Gain a positive testimonial from the client for the practitioner's portfolio.

## Treatable Conditions

### Telangiectasis

A Greek word meaning 'end vessel dilation'. These are not 'broken capillaries' as so often named, but permanently dilated capillaries. The thin, singular cell wall structure of the fine facial capillaries dilate and constrict constantly in order to control the body temperature and their elasticity weakens and they can become permanently dilated. Their visibility is often exacerbated by the breakdown of the skin's supporting network of collagen and elastin and ageing, thinning skin.

There are numerous causes for Telangiectasia including: ageing, hereditary and genetic causes, pregnancy, hormones, general skin fragility, smoking, extreme sports, temperature extremes and harsh weather exposure. They are very commonly seen in a maturing 'English rose' complexion.

A course of advanced electrolysis is often advised for telangiectasia so that treatments can be spaced out to prevent skin damage or hyper-pigmentation. Both Thermolysis and blend methods can be utilised, but the latter is only taught by a few specialists in this field. Diathermy is more commonly used, which involves a very accurate positioning of the probe over the blood vessel and a gentle tap that applies current to the skin's surface. This causes that tiny section of vessel to immediately disappear. Although this quick technique allows a number of small vessels to be treated in a small amount of time, care must be taken not to over treat and sessions are usually 15 minutes per cheek.

Although not considered a cause of telangiectasia, rosacea (and the medication for it) may be a related factor, with the two conditions often presenting simultaneously. Reducing the appearance of the blood vessels using electrolysis may initially trigger a rosacea attack and the client should be made aware of the possible trigger reaction. However this is relatively rare and only a temporary consequence of the long-term positive results.

### Campbell de Morgan Spots

Named after Campbell Grieg De Morgan (1811-1876) a British surgeon who was the first to note them, in medical literature these vascular blemishes are also known as Cherry Angioma or Blood Spots. They present themselves as slightly raised or dome shaped and are of unknown origin. They are mostly seen on the trunk in middle aged and elderly clients and are even more common in men than women. They are treated with Diathermy only. Larger ones (50p size+) will need more than one treatment. Smaller ones often disappear at time of treatment.

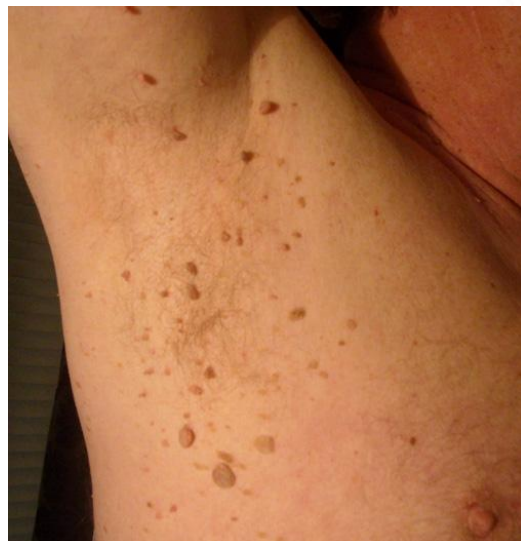### Spider Naevus

Spider Naevus a central dilated blood vessel, with smaller capillaries radiating from it like the legs of a spider can be individual isolated blemishes or can be multiple in areas such as the cheeks or chest area. They can, if apparent in isolation, be a result of a trauma to the skin, for example... a child following a minor mishap such as bumping into an object, can develop a spider naevus in the traumatised area. Certain conditions can make them worse including extreme heat and cold, obesity, pregnancy, stress or pressure on the area. Several spider naevus appearing spontaneously is a cause for concern as it might indicate liver disease. They can be treated with Blend or Diathermy methods although they can be quite resilient and more than one treatment may be necessary.

### Skin Tags (Fibroepithelial polyp/papilloma)

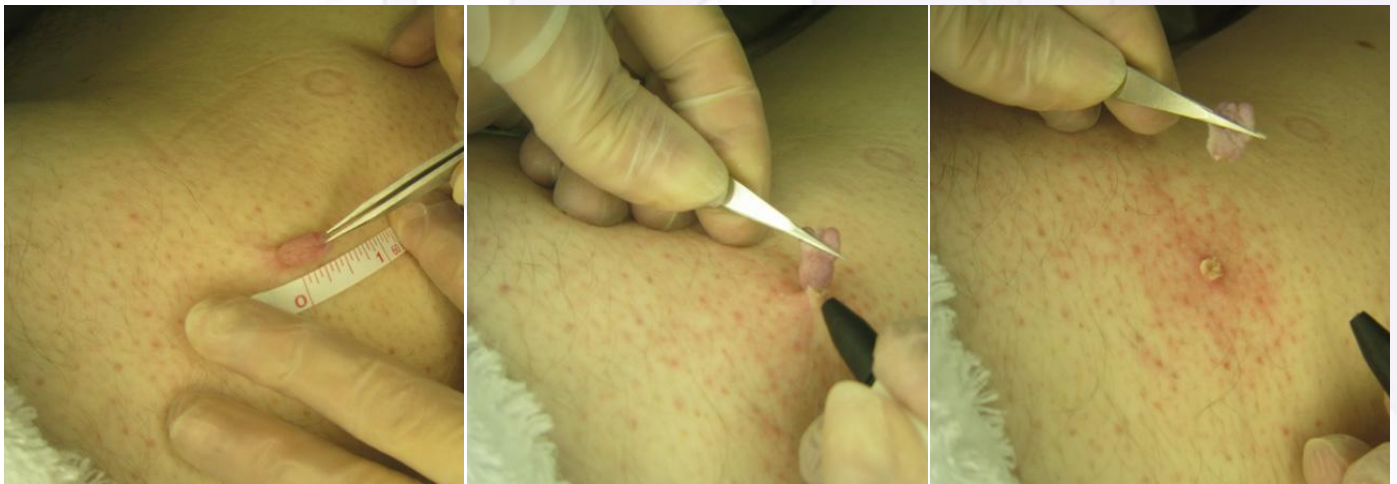Skin Tags are a common fibrous skin condition commonly found in areas of friction such as the axillae, under the breasts, groin or around the neck where necklaces or collars may irritate. Derived from epithelial cells and consisting of loose fibrous tissue they form single or multiple distributions and are often hyper-pigmented making them more obvious. They often present with a neck like a mushroom and vary in size from a tiny speck, smaller than a grain of uncooked rice, to the size of a large pea or larger. They are viral in nature (Human Papilloma Virus HPV) and whilst not infectious they can proliferate on individuals with some people suffering from hundreds of them.

Skin Tags are very easily treated using advanced electrolysis techniques and whether they are tiny ones between the eyelashes or large ones under the arms there is one of the advanced electrolysis techniques suitable for them. Areas of friction such as the under the breasts and under folds of skin on the overweight are very common areas to find these irritating blemishes. Advanced electrolysis is probably the quickest, easiest way of removing the problem in a safe and effective manner.



There are three different methods of skin tag removal for different types of tags and location:

1. For treatment of tags between the eyelashes, or for tiny tags around the neck or under the arms, the probe is gently rested on the skin tag and the current released. The heat generated causes the tag to stick to the probe and then just lifts off as if being melted from the skin. When performed correctly this method takes only seconds per tag removal.
2. When the location of the tag renders treatment difficult, another method involves insertion of the probe and then the application of current for a number of seconds to cut off the blood supply, which results in the tag immediately shrivelling and eventually (a day or two later) being sloughed off.
3. A third method involves supporting the tag with tweezers and using the very tip of the probe to continually tap away at the neck of the tag, which results in the immediate removal of the skin tag. Treatment is very fast and effective, taking only seconds depending on the size of the skin tag. The procedure is only a little uncomfortable with some clients experiencing no discomfort



## Milia

Lying very superficially under the epidermis milia present themselves as small white lipid-epithelium plugs which contain lamellated keratin deposits and often show as hard, solid lumps lying in the superficial papillary dermis. They are a retention of keratin and sebaceous material within the pilosebaceous duct, eccrine sweat duct, or the sebaceous collar surrounding vellus hair. Their exact cause is unknown although they are often related to diet with a high cholesterol count, excessive Vitamin C, too rich moisturising cream and are also associated with dry skin which can be acidic.

They can all be treated easily with advanced electrolysis techniques using diathermy (AC) which gently dries them up so that the hard keratinised centre is broken down and this will then be absorbed by the skin following treatment. This is a much gentler way to treat them, as opposed to removing them with a microlance, which can damage the skin. Milia can appear between the eyelashes, on the eyelid itself, the cheek area or anywhere on the face or neck where dry skin is present. They tend to grow in size, become harder (as the contents keratinize) and then become noticeable to the eye and cosmetically unattractive. Some people may only suffer one and others exhibit a proliferation of up to 40 – 60 of them at any one time.

## Warts

There are various types of warts, including flat (plane) raised (common) and verrucas (plantar). They are benign epidermal tumours which are contagious (human papilloma virus) and all can be treated. Warts can develop individually or in clusters and can spontaneously disappear. Plane or flat warts occur mostly on the face, backs of hands and wrists. Hygiene must be of the highest importance to avoid cross infection and if not treated they may spread. Treatment is performed using diathermy.

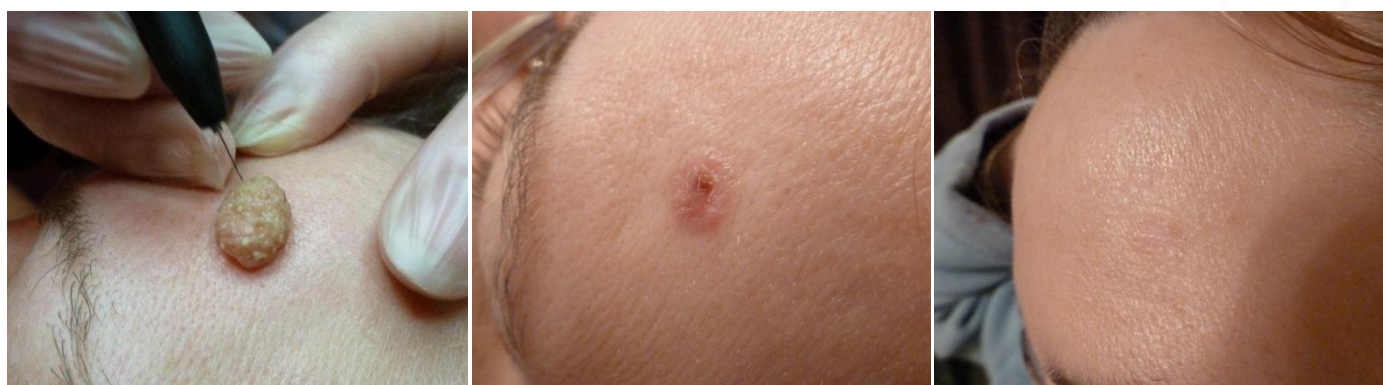**Seborrhoeic Keratosis** classified within the wart family but these differ in the fact that they are not contagious. They present as raised and appear frequently as several lesions on covered body sites and are also quite common on the face in older people. They are usually brown because of melanin and so can be mistaken for moles to the untrained eye. The dry, scaly, crusty appearance often with a cleft surface and a superficial 'stuck on' appearance are helpful identification points. They can be tiny or large even up to two inches across and can be removed with diathermy (AC) simply and effectively.

**Dermatosis Papulosa Nigra** is peculiar to black skin and is a common papular disorder which develops in adolescence. The lesions are histologically identical to seborrhoea keratosis and present as smooth, dome shaped, brown to black papules seen mainly on the cheeks, neck and upper chest. These are generally a very common disorder and the famous actor Morgan Freeman has many of these on his face. They are very easily and successfully treated using diathermy and advanced electrolysis techniques. Great care must be taken not to allow the current to spread onto the surrounding skin due to the darker nature of the skin tone.

## Moles

Hairs from moles are easily treated by those trained in advanced electrolysis techniques although insurance may insist upon a GP's written agreement is obtained prior to treatment. Once treatment is started it is normal for the mole to reduce in size and colour. Hairs in moles are generally deep terminal hairs with a very rich blood and nerve supply to them. Repeat treatments, as with hair removal electrolysis are required and blend or diathermy can be used.

A mole itself is easily treated but rather than 'removing' we 'visibly reduce the appearance' of the mole. A number of techniques are taught on the Sterex courses, each extremely successful and all using diathermy (AC). The first treatment will visibly reduce the mole by up to three quarters of its size and then a follow up treatment can smooth it so that it is flat to the skin. The colour can never be guaranteed to exactly match the surrounding skin but if the mole is much darker the remaining skin, following treatment, will almost certainly be lighter.



Hairy mole before treatment

One month after treatment

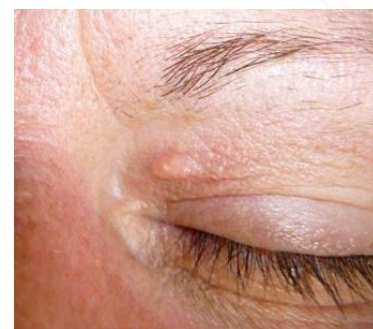Final result

## Age Spots

Age Spots are caused by an accumulation of a yellow pigment called lipofuscin from ageing of the collagen producing cells. They are very common on the hands and face of middle aged and elderly patients and are usually despised by them as they are so recognisably a sign of increasing age. Chemical peels and skin whitening products are commonly used for treatment but electrolysis is also very effective. Using a very fine electrolysis needle and diathermy (AC) current a tiny section of the age spot is lifted from the underlying tissue and the colour underneath is observed. If the tiny area exposed is lighter in colour removal can go ahead with varying degrees of success. If the pigment underneath the tiny section lifted is the same colour as the age spot itself the pigment goes deep into the dermis and treatment will not be successful.

## Xanthomas

Xanthomas are deposits of fatty material under the skin and range in size from 6mm to more than 7cm diameter. They are associated with a symptom of metabolic disorders such as diabetes or high cholesterol. Xanthelasma Palpebera is the common type which appears on the eyelids and presents itself as flat yellowish growths on the eyelid close to the nose. Resembling a butter bean and causing no pain they are successfully treated using Diathermy. They reduce in size and appearance although the milky yellowy colour remains and more than one treatment is often required over a period of time.



## Syringoma

Syringomas are benign eccrine gland tumours presenting as flattish papules or plates found around the eye socket area in particular under the eye and are non-contagious flesh colour elevations of the skin. They range from 1–3 mm in diameter and are firm to the touch. They are easily treated with diathermy and advanced electrolysis techniques.

## Molluscum Contagiosum

This is a common condition of small 'warty pearly' white or slightly pink lumps on the skin each lump being round, firm and about 1-5mm across. It is a contagious virus and typically each molluscum lasts about 6-12 weeks, crusts

over and then goes. New ones tend to appear as old ones fade as the virus spreads to other areas of skin. Therefore 'crops' appear and go for several months and it can take 12-18 months before the last goes completely. Electrolysis using diathermy can be successfully utilised to desiccate each molluscum.

## Sebaceous Cysts

Sebaceous Cyst or (Steatoma) is retention of keratin trapped under the surface of the skin trapped within a sebaceous sac which is created from skin cells. They are painless, slow-growing, small bumps or lumps that move freely under the skin and to the trained eye, are usually easily diagnosed by their appearance.

Sebaceous cysts are formed often due to swollen hair follicles, blocked glands, skin trauma and higher levels of testosterone in the body. Keratin is an extremely strong protein found naturally within the body and is a major component in skin, hair, nails and teeth. It is predominantly made up of dead cells and amino acids which combine to form keratin and these contain unique properties rendering it hard or soft. If the dead cells are kept in good condition, they will serve as an insulating layer to protect the delicate new keratin below them.

The size of the cyst can vary from a pea to an egg, and the areas most affected are those where there are more sebaceous glands, i.e. face, chest, scalp and back, although sometimes they also appear in the underarm and can be found on the trunk and the vaginal area or other parts of the genitalia. They may have an open or closed top and treatment is dependent upon the size and location.

If small, the most gentle and least invasive method is electrolysis which is proving very successful. If electrolysis is performed it may be necessary to treat the nodule more than once depending on its size and location and successful treatment cannot always be guaranteed as every cyst is very individual in nature.

An electrolysis needle is inserted into the sebaceous cyst a number of times and the A/C, RF diathermy current is expelled and held within the skin overgrowth. The heat softens the contents of the cyst and immediately following the application of the current the contents (or some of the contents) may be able to be excised from the nodule. This, however, is not always the case and apart from generalised erythema the nodule may not look any different initially following treatment. Over the next week or so the nodule should reduce in size, irrespective of whether contents are expelled. Further treatment will almost certainly be required and no guarantees offered, however positive feedback is forthcoming from those treated by the use of electrolysis.

## Where do I train?

- Sterex offers FREE entry onto their website thereby providing free advertising
- Sterex teaches all methods of red vein therapy
- Sterex courses cover 21 skin disorders and are the most prolific trainers in their field
- Sterex teach small groups on a 4 – 1 ratio
- Sterex provide a variety of models and to a degree, the variety of disorders presented to be treated
- Sterex offers an established name recognised by the consumer
- A Sterex Hotline support telephone number offers ongoing help and support
- Highly qualified and experienced Sterex lecturers run Sterex ACP courses

For further information email: [training@sterex.com](mailto:training@sterex.com) Tel: 0121 708 2404 Web: [www.sterex.com](http://www.sterex.com)



Elaine Stoddart is Director of Education for Sterex Electrolysis International Limited – the leading electrolysis brand and is a highly qualified and experienced specialist electrologist with over 25 years of experience. Through Sterex she has trained Surgeons, Doctors, Nurses and many other medical practitioners and Therapists in Electrolysis and Advanced Electrolysis/Cosmetic Procedures and runs her own practices in Harley Street and Bucks. She is the most prolific trainer in Advanced Electrolysis/ Cosmetic Procedures in the UK and has pioneered the first ever Transgender electrolysis course in the UK.

Respected author of two Level 3 Beauty Therapy books and accomplished international speaker in Electrolysis and Advanced Electrolysis/ Cosmetic Procedures she is a member of the British Association & Institute of Electrolysis (BIAE), City & Guilds National Advisory Committee (NAC), Royal Society of Medicine (RSM) and a member of the British Association of Therapists and Cosmetologists (BABTAC). Elaine wrote and delivered a number of educational podcasts for BABTAC in 2009 and has appeared on BBC work place skills educational programmes.

**If you have any comments or suggestions regarding this article, please email [clinicarea@consultingroom.com](mailto:clinicarea@consultingroom.com)**